

Cleidocranial Dysplasia Revisited: A Closer View from a Periodontal Perspective

Harpreet Singh Grover¹, Pradhuman Verma² and Kanika Verma Gupta³

¹*Department of Periodontics, ²Department of Oral Medicine & Radiology, ³Department of Pedodontics & Preventive Dentistry, Desh Baghat Dental College & Hospital, Muktsar, Punjab, India*

KEYWORDS Supernumerary Teeth. Hypoplastic Clavicles. Acellular Cementum. Wormian Bones

ABSTRACT Cleidocranial dysplasia, a rare developmental condition in which the leading features are: aplasia or hypoplasia of the clavicles, exaggerated development of the transverse diameter of the cranium, delayed closure of the fontanelles, and disorders of the jaws and dentition. It is associated with mutation of Runt related gene 2 (RUNX2), also referred to as Core binding factor 1 (CBFA1) on chromosome 6p21, a transcriptional factor essential for osteoblast differentiation and bone formation. Not many periodontists routinely have the opportunity to treat patients with this rare genetic disorder and as a result often remain unsure of the periodontal treatment needs in such patients. The present case report is being presented to address this very gap between knowledge and the practical clinical applications.

INTRODUCTION

Cleidocranial dysplasia was referred to as cleidocranial dysostosis prior to the conference on the nomenclature for constitutional disorders of bone held in Paris 1969. The syndrome was first described as a rare developmental condition by Marie et al. (1898) in which the leading features were (1) aplasia or hypoplasia of the clavicles, (2) exaggerated development of the transverse diameter of the cranium, (3) delayed closure of the fontanelles, and (4) disorders of the jaws and dentition cited by Salem (1990).

Pathogenesis

Cleidocranial dysplasia is associated with mutation of Runt related gene 2 (RUNX2), also referred to as Core binding factor 1 (CBFA1) on chromosome 6p21, a transcriptional factor essential for osteoblast differentiation and bone formation. The RUNX2 gene provides instructions for making a protein that is involved in bone and cartilage development and its maintenance. This protein is a transcription factor, which means it attaches (binds) to specific regions

of DNA and helps control the activity of particular genes. Cbfa1 has been described as a potential “master gene” for osteogenic differentiation as referred by Gulati et al. (2001).

Some mutations change one protein building block (amino acid) in the RUNX2 protein. Other mutations introduce a premature stop signal that results in an abnormally short protein. Occasionally, the entire gene is missing. The gene has been mapped to chromosome 6p21 in the region containing Cbfa1, which controls the differentiation of precursor cells into osteoblasts. Both dominant and recessive patterns of inheritance have been described. Javaris et al. (1974) explained that spontaneous mutation occurs in 20-40% of cleidocranial dysplasia patients, while reason remains unknown in the rest. One in a million people are affected by this rare genetic disorder as explained by Suba et al. (2005).

Clinical Features

General Features: The clavicles maybe hypoplastic or partially or completely absent. Because of this, the patient is able to press his shoulders together in front of the sternum to varying degrees. The head is large and out of proportion to the skeletal structure of the face, with a bulging forehead and prominent cranial bossing. The facial bones and paranasal sinuses are hypoplastic giving the face a proportionately diminished appearance. Hypertelorism is frequently present. The sagittal suture is often depressed, which causes the skull to have a broad surface. Wormian bones are seen in the skull

Address for correspondence:

Dr. Kanika Gupta Verma

B.D.S, M.I.D.A, M.D.S (Pedodontist)

Assistant Professor

Department of Pedodontics

Desh Baghat Dental College & Hospital,

Muktsar, Punjab, India

Mobile: +91 9317524546 , 9316162692.

E-mail: drguptakanika@yahoo.co.in,

drguptakanika@gmail.com

(due to secondary centers of ossification). The fontanels show delayed or absent ossification. Hall (1982) suggested that many patients have decreased auditory acuity as a result of concentric narrowing of the external auditory canal. Maxillary hypoplasia gives the mandible a prognathic appearance. Knock knee is a common finding. Hand anomalies may include asymmetric length of fingers.

Facial Features: Growth in maxillary height was severely reduced, primarily because the resorptive lowering of the nasal floor was minimal while the amount of bone apposition on the orbital floor and the alveolar process was lesser than expected. Condylar growth direction was vertical giving rise to a forward rotation of the mandible in relation to the anterior cranial base. The expected resorptive remodeling below the mandibular angle and anteriorly on the ramus was negligible. The low maxilla, in combination with a marked forward mandibular rotation in cases with unstable occlusion as a consequence of eruption problems in the permanent dentition, gave rise to a diminished anterior facial height as suggested by Shafer et al. (1984).

The narrow, highly arched palate, the retention of deciduous teeth, delayed eruption of permanent teeth, and the presence of large numbers of impacted supernumerary teeth are all classical oral findings in cleidocranial dysplasia. It is well known that a complete layer of acellular cementum usually covers the dentin of the roots of teeth, although sometimes this layer is incomplete near the apex. Overlying the acellular cementum, in the apical half of the roots, are layers of cellular cementum, which increase in thickness with age. It was noted that both erupted and unerupted permanent teeth of patients with CCD exhibited a lack of cellular cementum.

The observation of a preponderance of acellular cementum reported by Rushton (1956) may not be a distinguishing characteristic of teeth affected by CCD. Their study suggested that the difference in cementum is not significant between CCD patients and control subjects and, therefore, the amount of cellular or acellular cementum may not be a factor in the increased number of nonerupted teeth in those suffering from CCD suggested by Counts et al. (2001).

Haploinsufficiency of Runx2/Cbfa1 is insufficient for the active alveolar bone resorption essential for the prompt timing of tooth eruption. Mundlos (1999) suggested the possibility that

impaired recruitment of osteoclasts is one of the cellular mechanisms of delayed tooth eruption in CCD patients.

It is suggested that the short roots with spike like apices often seen in unerupted teeth in CCD are due to inadequate bone resorption. Also occurrence of ankylosis in the deciduous teeth is indicative of tooth resorption which has ceased and the new bone that has been formed is very dense. Deciduous teeth and first permanent molars come into normal occlusion because there is little or no bone over them that may impede their eruption as explained by Calderoni et al. (1982).

It has been hypothesized that the dental lamina for both primary and permanent dentition is normal, but it does not resolve completely and therefore may form supernumerary teeth. An increase in odontogenesis leads to an excessive number of supernumerary teeth. Kirson et al (1982) cited that there is a predisposition to develop numerous supernumerary teeth in the mandibular premolar and maxillary anterior region.

Treatment

Treatment of CCD includes dental procedures to address the affects of retention of deciduous dentition, presence of supernumerary teeth, non-eruption of the permanent dentition along with related malocclusion and periodontal conditions accompanying them. Maintenance of periodontal health is of prime concern in order to allow for an absolute and complete oral rehabilitation of the patient.

It was found that a diagnosis of the disorder should be made early so that formation of supernumerary teeth can be diagnosed and early intervention undertaken. Supernumerary teeth that pose a significant obstacle to tooth eruption begin their mineralization 4 years later than the corresponding permanent teeth. It should be possible to diagnose supernumerary incisors at about 5-7 years of age and supernumerary canines and premolars a few years later. When root length of the normal permanent teeth has reached about one-third of its final length, the overlying supernumerary teeth should be removed, together with overlying bone and primary teeth. In regions where no supernumerary teeth are formed, eruption may also be improved by removal of the primary teeth and surgical exposure of the underlying permanent teeth as given by Jensen et al. (1992).

Calculus	{	4	4	5				1	2	3			3	4	3								
		4	4	4				2	2	2			3	3	2								
Periodontal pocket	{	5	4	4	4	4	3			2	3	2	2	2	2			3	3	4	4	4	3
		5	4	4	4	3	3			3	3	2	3	2	3			4	4	4	4	3	3
Tooth number	{	8	7	6	5	4	3	2	1	1	2	3	4	5	6	7	8						
		8	7	6	5	4	3	2	1	1	2	3	4	5	6	7	8						
Periodontal pocket	{	4	4	4	4	2	2	3	2			2	2					3	3	5	5	5	4
		4	3	4	3	3	3	2	2			2	2					4	4	4	5	4	5
Calculus	{	4	4	3	4					3				3	5	4							
		3	4	4	5					3				4	5	4							

Fig. 1. Calculus grades and periodontal pocket depths

Simply the extraction of primary teeth to promote eruption of the permanent successors has been found to be unsuccessful. Hence, orthodontic extrusion of the impacted teeth is also required.

Case Report

A 27-year old male patient having Cleidocranial Dysplasia was referred to the Department of Periodontics with a chief complaint of bleeding gums and pus discharge from multiple sites in the gums for periodontal treatment. On performing an oral examination it was noticed that the patient had several missing and unerupted

teeth. Over-retained deciduous molars and incisors were present. Pus was easily expressed from around these teeth. Bleeding on probing was present. The color of the gingiva was reddish pink with evident pigmentation. Periodontal pockets were seen in relation to 16, 17, 25, 26, 36, 37, 46 and 47 (Fig. 1). Grade 1 mobility was present in relation to 16, 17, 25, 26, 75 and grade 2 in relation to 84 and 85. Furcation involvement was noticed in 26, 75, 36, 84, 85 and 46. 11 and 21 were mesially rotated (Fig. 2). The patient's Loe H. Gingival Index Score was 2 (Moderate inflammation, edema, redness and bleeding on probing) and Russell AL Periodontal Index Score was 6.

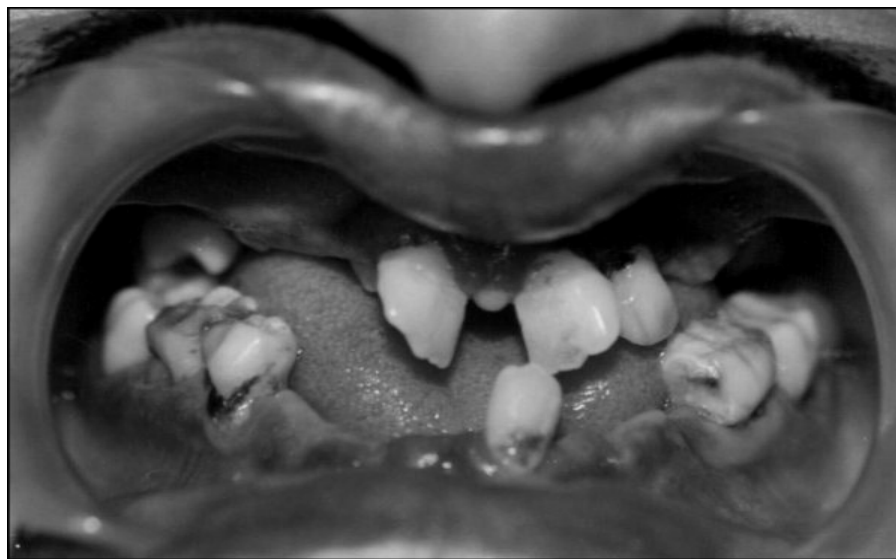

Fig. 2. Intraoral photograph showing periodontal status of patient

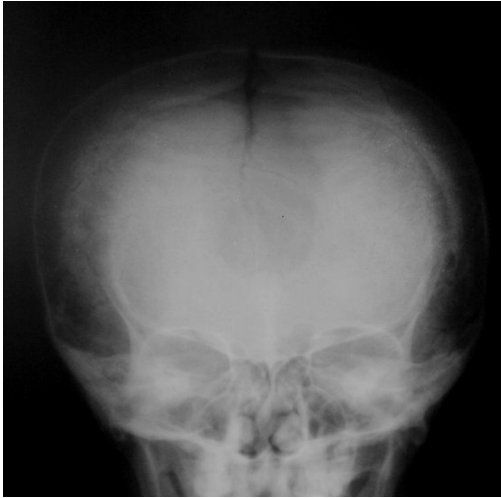

Fig. 3. PA view of the skull revealed widely open fontanelles and sutures

The extraoral findings were concurrent with the classical findings in a patient of CCD including: high prominent forehead, depressed nasal bridge, frontal bossing, hypoplasia of the maxilla along with false prognathism of the mandible resulting in a Dish Face appearance.

The patient also exhibited features such as drooping shoulders with narrow and funnel shaped chest, excessive joint mobility and an ability to easily approximate his shoulders in front of the sternum.

Radiographic examination in the PA view of the skull revealed widely open fontanelles and sutures (Fig. 3). Lateral view of the skull showed

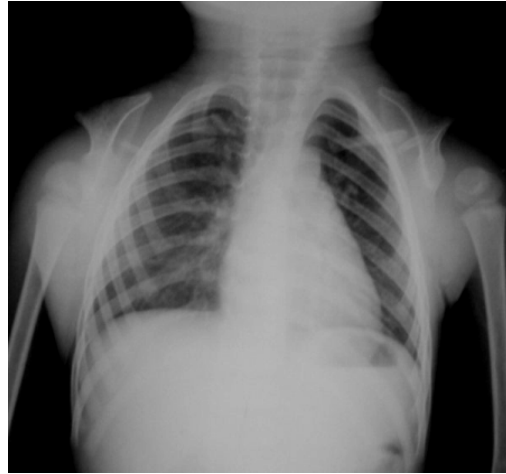


Fig. 4. X-Ray of the chest showed asymmetrically deficient clavicles along with narrowing of the chest cage

enlarged skull bones along with multiple wormian bones. X-Ray of the chest showed asymmetrically deficient clavicles along with narrowing of the chest cage (Fig. 4). OPG revealed multiple retained deciduous and impacted teeth (Fig. 5).

Treatment Plan: Full mouth scaling and root planing has been done. The patient has been referred to the department of oral surgery for extraction of 18, 75, 38, 84 and 85. Following this we plan to remove the overlying bone and expose the unerupted teeth i.e. 14, 13, 23, 24, 35, 34, 33, 32, 31, 41, 42, 43, 44 and 45 which would then be orthodontically extruded. 11 and 21 would

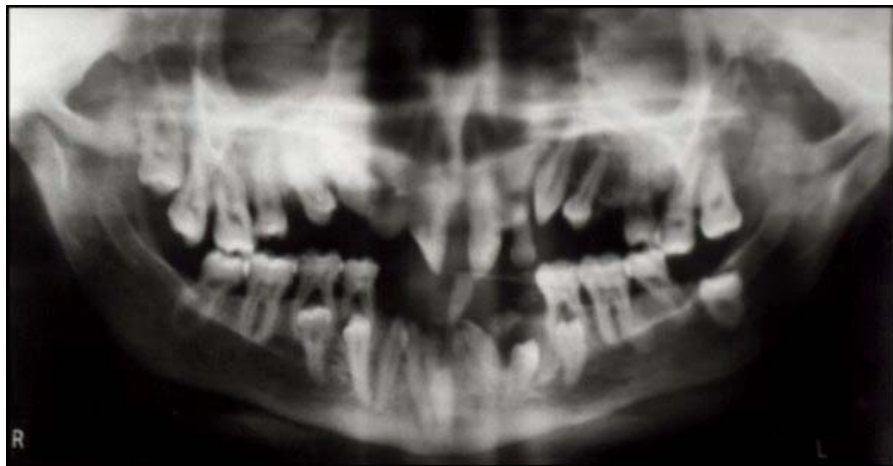

Fig. 5. OPG showing multiple retained deciduous and impacted teeth

also be orthodontically treated and de-rotated. Simultaneously periodontal treatment would be undertaken i.e. full thickness flap and debridement in relation to 17,16,26,36,37,46 and 47.

CONCLUSION

Not many periodontists routinely have the opportunity to treat patients with this rare genetic disorder and as a result often remain unsure of the periodontal treatment needs in such patients. The present case report is being presented to address this very gap between knowledge and the practical clinical applications. It is hoped that by looking at and treating such cases from a periodontal perspective will help the fellow periodontists to gain their rightful place in the multi-disciplinary treatment approach towards treating such patients.

REFERENCES

- Calderoni P, Soncini G, Zocchi D 1982. Cleidocranial dysostosis (description of a case). *Chir Organi Mov*, 67: 353-356.
- Counts AL, Rohrer MD, Prasad H 2001. An assessment of root cementum in cleidocranial dysplasia. *Angle Orthod*, 71: 293-298
- Gulati S, Kabra M 2001. Cleidocranial dysplasia. *J. Post Grad Med*, 3: 204-205.
- Hall BD 1982. Syndromes and situations associated with congenital clavicular hypoplasia or agenesis. *Prog Clinic Biol Res*, 184: 279-288.
- Javaris JL, Keats TE 1974. Cleidocranial dysostosis. A review of 40 cases. *Am J Radiol*, 28: 14-21.
- Jensen BL, Kreiborg S 1992. Dental treatment strategies in cleidocranial dysplasia. *Br Dent J*, 6: 243-247.
- Kirson LE, Scheiber RE, Tomaro AJ 1982. Multiple impacted teeth in cleidocranial dysostosis. *Oral Surg*, 5: 604-606.
- Marie P, Sainon P 1898. Sur la dysostose cleidocranienne hereditaire. *Rev Neurol*, 6: 835-841.
- Mundlos S 1999. Cleidocranial dysplasia: clinical and molecular genetics. *J Med Genet*, 36: 177-182.
- Rushton MA 1956. Anatomy of cementum in Cleidocranial Dysostosis. *Br Dent J*, 6: 100-111.
- Salem G 1990. Nonfamilial cleidocranial dysplasia (dysostosis): A case report. *Saudi Dental Journal*, 17: 112-115.
- Shafer WGI, Hine MK, Levy BM 1984. *Diseases of bone and joints: Cleidocranial dysplasia. Oral Pathology. Philadelphia: WB Saunders Co*, 4: 363-365.
- Suba Z, Balaton G, Gyulai-Gaál S, Balaton P et al. 2005. Cleidocranial dysplasia: Diagnostic criteria and combined treatment. *J of Craniofac Surg*, 16: 1122-112.